



## **Pseudozyma aphidis fungemia after abdominal surgery: First adult case**

Agathe Herb, Alina-Marcela Sabou, Jean-Baptiste Delhorme, Patrick Pessaux,  
Didier Mutter, Ermanno Candolfi, Valerie Bru

### **► To cite this version:**

Agathe Herb, Alina-Marcela Sabou, Jean-Baptiste Delhorme, Patrick Pessaux, Didier Mutter, et al..  
Pseudozyma aphidis fungemia after abdominal surgery: First adult case. Medical Mycology Case  
Reports, 2015, 8, pp.37-39. 10.1016/j.mmcr.2015.03.001 . hal-02492427


**HAL Id: hal-02492427**

**<https://hal.science/hal-02492427>**

Submitted on 26 Feb 2020

**HAL** is a multi-disciplinary open access archive for the deposit and dissemination of scientific research documents, whether they are published or not. The documents may come from teaching and research institutions in France or abroad, or from public or private research centers.

L'archive ouverte pluridisciplinaire **HAL**, est destinée au dépôt et à la diffusion de documents scientifiques de niveau recherche, publiés ou non, émanant des établissements d'enseignement et de recherche français ou étrangers, des laboratoires publics ou privés.



## *Pseudozyma aphidis* fungemia after abdominal surgery: First adult case



Agathe Herb<sup>a</sup>, Marcela Sabou<sup>a,b</sup>, Jean-Baptiste Delhorme<sup>c</sup>, Patrick Pessaux<sup>c</sup>,  
Didier Mutter<sup>c</sup>, Ermanno Candolfi<sup>a,b</sup>, Valérie Letscher-Bru<sup>a,b,\*</sup>

<sup>a</sup> Laboratoire de Mycologie Médicale, Plateau Technique de Microbiologie, Hôpitaux Universitaires de Strasbourg, 1 Place de l'Hôpital, 67000 Strasbourg, France

<sup>b</sup> Institut de Parasitologie et de Pathologie Tropicale, EA7292, Fédération de Médecine Translationnelle, Université de Strasbourg, 3 rue Koeberlé, 67000 Strasbourg, France

<sup>c</sup> Service de Chirurgie Digestive, Nouvel Hôpital Civil, Hôpitaux Universitaires de Strasbourg, 1 Place de l'Hôpital, 67000 Strasbourg, France

### ARTICLE INFO

#### Article history:

Received 7 February 2015

Received in revised form

24 February 2015

Accepted 5 March 2015

Available online 6 March 2015

#### Keywords:

*Pseudozyma aphidis*

Fungemia

Antifungal susceptibility

### ABSTRACT

*Pseudozyma aphidis* is an environmental Basidiomycete yeast, and has been involved in the ten past years in rare cases of invasive infection. *Pseudozyma* species are naturally resistant to caspofungin and often present decreased susceptibility or resistance to fluconazole. This fungus may be difficult to recognize and misidentifications are reported with conventional phenotypical methods. We report a case of *P. aphidis* invasive infection in an adult with a metastatic ampulloma who had gone through digestive surgery.

© 2015 The Authors. International Society for Human and Animal Mycology Published by Elsevier B.V. This is an open access article under the CC BY-NC-ND license (<http://creativecommons.org/licenses/by-nc-nd/4.0/>).

### 1. Introduction

Rare yeasts are considered as having a low pathogenicity, but are still responsible for 1.1–5.1% of fungemias. This is most likely due to the increasing number of immunocompromised patients and also to the improvement of mycological diagnosis, especially molecular biology techniques [1,2].

Indeed, in the past decades, we have seen the emergence of yeasts that had never been described as invasive pathogens before, such as *Saccharomyces* spp., *Rhodotorula* spp. or *Trichosporon* spp. A recent study has looked more closely into rare yeast infections in patients with cancer, and found that the incidence of these infections increased from 1.8 to 2.35 cases per 100,000 patient-days between 1998 and 2010 [3]. In this study, 95% of the patients had a central venous catheter, and the presence of a catheter was considered responsible for 45% of those infections.

The anamorphic basidiomycetous genus *Pseudozyma* belongs to the Ustilaginomycetes class and includes 16 species. *Pseudozyma* species are common environmental yeasts generally isolated from plant leaves, flowers or soil. Some species have recently (since 2003) been involved in invasive infections, such as fungemia [4–8], pulmonary infection [9], brain abscess [10], and mycetoma [11].

We here report what we believe, to our best knowledge, to be the first case of a *Pseudozyma aphidis* invasive infection in an adult with a metastatic ampulloma, who underwent heavy digestive surgery. The evolution was favorable after two weeks of intravenous liposomal amphotericin B.

### 2. Case report

A 68 year old woman was hospitalized in the University Hospital of Strasbourg, France. She was admitted to a digestive surgery unit for the management of a metastatic adenocarcinoma of the ampulla of Vater. She had not yet undergone chemotherapy, and went through a pancreaticoduodenectomy and lymphadenectomy on April 23rd 2014 (day 0), during which a sample of bile was taken and sent to the Bacteriology Laboratory. She received no antifungal chemoprophylaxis. Subsequently to this surgery, a central venous catheter and drains were placed. Because the bile culture was positive for *Enterococcus faecalis* and *Klebsiella pneumoniae* on day +1, a bi-antibiotherapy was started with meropenem and vancomycin for 19 days.

On day +22, she started to shiver with fever of 38.5 °C. Two blood cultures were then drawn the same day on a peripheral vein onto BACTEC™ Mycosis-IC/F and BACTEC™ Plus Aerobic/F Medium, and remained negative after seven days of incubation in a BACTEC™ FX (Becton Dickinson). Two others were drawn on day +23 on the central venous catheter onto BACTEC™ Mycosis-IC/F

\* Corresponding author at: Institut de Parasitologie et de Pathologie Tropicale, EA7292, Fédération de Médecine Translationnelle, Université de Strasbourg, 3 rue Koeberlé, 67000 Strasbourg, France.

E-mail address: [letscher@unistra.fr](mailto:letscher@unistra.fr) (V. Letscher-Bru).

and BACTEC™ Plus Aerobic/F Medium and were both positive on day +26 and on day +27, which is after 84 h (Mycosis) and 100 h (Aerobic/F Medium) of incubation at 35 °C. Microscopic examination of the blood cultures revealed unusual fungal elements.

A treatment with intravenous fluconazole 800 mg/day had been initiated on the evening of day +26, and was then switched to liposomal amphotericin B 3 mg/kg/day on the next day in order to have a larger antifungal spectrum.

The central venous catheter was withdrawn on day +23 and sent to the Bacteriology Laboratory of the hospital, where it remained negative after 48 h of incubation. Cultures were then eliminated according to bacteriological procedures. The control blood cultures, taken on a peripheral vein after the catheter removal, remained negative. No other specimen was addressed to the Mycology Laboratory.

The patient then developed a septic shock on day +27. Blood cultures drawn that same day on a peripheral vein, on an arterial catheter and on a central venous catheter were positive to *Candida albicans* and *Candida glabrata*. The patient was transferred to an intensive care unit. The evolution was favorable, and she was admitted back in the digestive surgery unit, where the liposomal amphotericin B was continued on for a total of two weeks.

The first positive blood cultures showed unusual fungal elements at direct examination, with short hyphae and fusiform cells with polar buddings (Fig. 1).

The blood was then subcultured on chromID™ *Candida* agar (Biomérieux, France) and on Sabouraud-Chloramphenicol-Agar at 27 °C and 35 °C. The isolate grew in about 24 h on both media. A better growth was observed at 27 °C. The colonies were first blue on the chromogenic medium, and then they produced a yellow-beige pigment, which was also the color observed on the Sabouraud-Chloramphenicol-Agar (Figs. 2 and 3). After several days of culture, the colonies looked tan, dry and wrinkled.

Microscopic examination of the colonies showed morphological aspects similar to those observed on positive blood cultures.

An analysis of the isolate on a Microflex™ MALDI-TOF mass spectrometer (Bruker, Germany) using the Biotyper Software (Bruker), was performed but was inconclusive as *P. aphidis* was suggested, but with an insufficient score (between 1.5 and 1.6).

The APID 32C strip (bioMérieux, France) was also inconclusive. The yeast was urease positive and nitrate positive.

Morphological study on Potato-Carrot-Bile medium (Bio-Rad, USA) incubated in a semi anaerobiosis at 27 °C produced more regular elements compatible with the genus *Pseudozyma* (Fig. 4).

Final identification was obtained by sequencing (GATC Biotech AG, Germany) of the ITS region followed by GenBank and CBS analysis, giving a 99% and a 99.7% match to *P. aphidis* (sequences

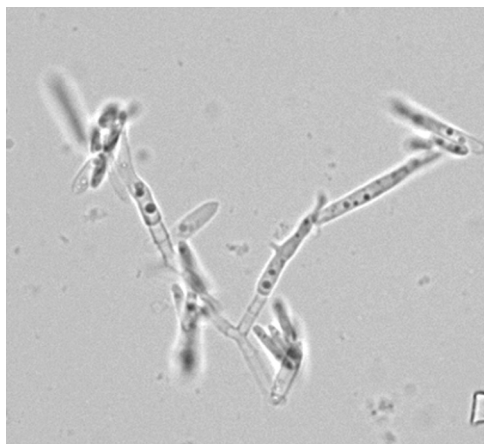


Fig. 1. Direct examination of the first positive blood culture.

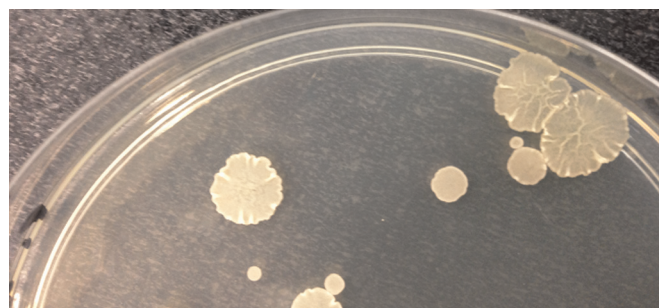


Fig. 2. *P. aphidis* colonies on chromID *Candida* agar after 8 days of incubation at 27 °C. The reverse of some colonies is blue.



Fig. 3. *P. aphidis* colonies on a Sabouraud Chloramphenicol agar after 4 days of incubation at 27 °C.

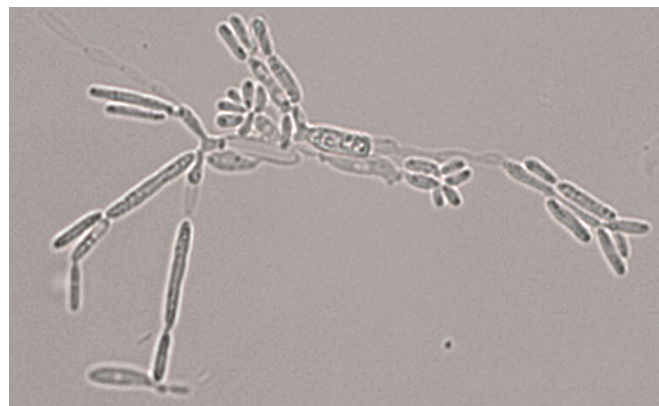

Fig. 4. Potato Carrot Bile Agar slide culture after 4 days of incubation at 27 °C.

JQ425372.1 and DQ778919.1), respectively.

The susceptibility of the isolate was tested by the Etest method (BioMérieux, France) on a RPMI medium, and it showed MIC values of 16 µg/mL for fluconazole, 0.19 µg/mL for itraconazole, 0.032 µg/mL for voriconazole, 0.094 µg/mL for posaconazole, 0.19 µg/mL for amphotericin B, > 32 µg/mL for caspofungin and > 32 µg/mL for flucytosine.

### 3. Discussion

Only a few *Pseudozyma* species have yet been reported as responsible for human invasive infection, in a limited number of cases. This is the fourth description of an invasive infection due to *P. aphidis*, and the first adult case. There is no report of documented colonization by this species in human patients. However Gil et al. have previously described respiratory colonization by *Pseudozyma* spp. without species identification [12]. Thirty strains were isolated from respiratory samples between 1997 and 2001. In all cases, the fungus was not isolated repeatedly and was considered as a colonizer; no antifungal treatment was considered

**Table 1**  
MICs of *P. aphidis* strains isolated from patients with invasive infection.

MIC (μg/mL)	<i>P. aphidis</i> isolates			
	Our isolate	Neonatal fungemia [4]	Fungemia in a short gut syndrome [5]	Pulmonary infection in a Burkitt [6]
Fluconazole	16	8	4	4
Itraconazole	0.19	0.03	0.125	0.25
Voriconazole	0.032	0.03		0.03
Posaconazole	0.094	0.03		
Isavuconazole		0.25		
Amphotericin B	0.19	0.03	0.25	0.25
Flucytosine	> 32	> 64		
Caspofungin	> 32	> 8		
Micafungin		> 8		> 4
Anidulafungin				> 4

necessary in these patients.

*P. aphidis* infections might be underdiagnosed, due to the fact that, at the moment, only sequencing allows an accurate identification of this yeast. Misidentifications as *Cryptococcus* or *Trichosporon* species have been described with the VITEK 2 (bioMérieux), The ID32C® (bioMérieux), the RapID Yeast Plus® (Remel) systems [8,12]. For our isolate, mass spectrometry analysis suggested *P. aphidis* but with a low score, which is most likely due to an insufficient number of spectra in the databank, and the API 32C identification algorithm does not include this species in its databank.

The risk factors described in all reports of invasive *Pseudozyma* infection were immunosuppression, neoplastic diseases, impaired mucosal defenses and foreign material, such as a central venous catheter. In our case, the patient had several risk factors: a metastatic adenocarcinoma of the ampulla of Vater, abdominal surgery and a central venous catheter. Her blood count was normal and did not reveal any cytopenia.

We could not document the portal of entry of the infection; however the central venous catheter remains the most probable hypothesis, as the control blood cultures after its removal were negative.

The choice of the first line antifungal therapy is important in case of non-*Candida* yeasts, as many other genera are resistant to caspofungin and/or azoles.

Only a few data are available for *P. aphidis* in the literature. Table 1 resumes the characteristics of the strains isolated from known invasive infections. Fluconazole has generally high MIC, and all isolates were found resistant to flucytosin and echinocandins [4–6]. Our strain had a high MIC for itraconazole too, although some reports describe favorable outcomes after an itraconazole treatment [5,11]. Some reports about other *Pseudozyma* species mention also high MICs for fluconazole and itraconazole and resistance to flucytosine and echinocandins [6,7,11].

The ESCMID and the ECMM recommend a first line treatment of amphotericin B or voriconazole for *Pseudozyma* infections [2].

Indeed, several patients have been successfully treated with amphotericin B followed by voriconazole *per os* [4,9].

In our case, the patient had two weeks of liposomal amphotericin B, which seemed, in association with the removal of the central venous catheter, to have successfully treated the infection.

In conclusion, we need to be aware of the hypothesis of a *Pseudozyma* invasive infection when observing unusual yeasts. More generally, first-line treatment with a large spectrum antifungal should be preferred when unusual fungal elements are isolated from a deep site.

## Conflict of interest

There are none.

## References

- [1] M.C. Arendrup, B. Bruun, J.J. Christensen, K. Fuursted, H.K. Johansen, P. Kjaeldgaard, et al., National surveillance of fungemia in Denmark (2004 to 2009), *J. Clin. Microbiol.* 49 (2011) 325–334.
- [2] M.C. Arendrup, T. Boekhout, M. Akova, J.F. Meis, O.A. Cornely, O. Lortholary, et al., ESCMID and ECMM joint clinical guidelines for the diagnosis and management of rare invasive yeast infections, *Clin. Microbiol. Infect.* 20 (Suppl. 3) (2014) S76–S98.
- [3] M.N. Chitasombat, D.P. Kofteridis, Y. Jiang, J. Tarrand, R.E. Lewis, D. P. Kontoyiannis, Rare opportunistic (non-*Candida*, non-*Cryptococcus*) yeast bloodstream infections in patients with cancer, *J. Infect.* 64 (2012) 68–75.
- [4] A. Prakash, S. Wankhede, P.K. Singh, K. Agarwal, S. Kathuria, S. Sengupta, et al., First neonatal case of fungaemia due to *Pseudozyma aphidis* and a global literature review, *Mycoses* 57 (2014) 64–68.
- [5] S.S. Lin, T. Pranikoff, S.F. Smith, M.E. Brandt, K. Gilbert, E.L. Palavecino, et al., Central venous catheter infection associated with *Pseudozyma aphidis* in a child with short gut syndrome, *J. Med. Microbiol.* 57 (2008) 516–518.
- [6] T. Sugita, M. Takashima, N. Poonwan, N. Mekha, K. Malaithao, B. Thungmuthasawat, et al., The first isolation of Ustilaginomycetous anamorphic yeasts, *Pseudozyma* species, from patients' blood and a description of two new species: *P. Parantarctica* and *P. Thailandica*, *Microbiol. Immunol.* 47 (2003) 183–190.
- [7] N. Mekha, M. Takashima, J. Boon-Long, O. Cho, T. Sugita, Three new basidiomycetous yeasts, *Pseudozyma alboarmeniaca* sp. Nov., *Pseudozyma crassa* sp. Nov. and *Pseudozyma siamensis* sp. Nov. Isolated from Thai patients, *Microbiol. Immunol.* 58 (2014) 9–14.
- [8] W. Siddiqui, Y. Ahmed, H. Albrecht, S. Weissman, *Pseudozyma* spp catheter-associated blood stream infection, an emerging pathogen and brief literature review, *BMJ Case Rep.* (2014), <http://dx.doi.org/10.1136/bcr-2014-206369>, Published online: Dec 12.
- [9] A.M. Parahym, C.M. da Silva, F. Domingos Ide, S.S. Gonçalves, M. Rodrigues Mde, V.L. de Moraes, et al., Pulmonary infection due to *Pseudozyma aphidis* in a patient with Burkitt lymphoma: first case report, *Diagn. Microbiol. Infect. Dis.* 75 (2013) 104–106.
- [10] S. Hwang, J. Kim, S. Yoon, Y. Cha, M. Kim, D. Yong, et al., First report of brain abscess associated with *Pseudozyma* species in a patient with astrocytoma, *Korean J. Lab. Med.* 30 (2010) 284–288.
- [11] B. Chen, L.Y. Zhu, X. Xuan, L.J. Wu, T.L. Zhou, X.Q. Zhang, et al., Isolation of both *Pseudozyma aphidis* and *Nocardia otitidiscaviarum* from a mycetoma on the leg, *Int. J. Dermatol.* 50 (2011) 714–719.
- [12] E. Gil, M.T. Durán, J.L. Rodríguez-Tudela, M. Cuenca-Estrella, M. Cartelle, et al., *Pseudozyma* sp.: colonizer of the respiratory tract in critical patients, *Enferm. Infecc. Microbiol. Clin.* 21 (2003) 65.